La Ginecologia estetica e funzionale: di cosa stiamo parlando? In Italia e nel mondo

Milano 22-23 GIUGNO 2018

Pietro Saccucci
Obstetrics and Gynecology Dpt
San Filippo Neri Hospital – Rome
pietro.saccucci@aslroma1.it

L’aumento della richiesta di trattamenti cosmetici ginecologici

- **Aumento dell’informazione attraverso i mass media**
- **La somministrazione di cure sta diventando sempre di più un rapporto tra la richiesta e l’offerta**
- **L’influenza delle opinioni dei medici**

L’aumento della richiesta di trattamenti

- **Impatto sulla qualità di vita**
- **Alcune condizioni fastidiose hanno un risvolto psicologico**
- **Vi possono essere pareri differenti tra sanitari sulla necessità di trattamenti**
- **Molte alterazioni non sono letali**

Searches
Professional vs Popular

- ‘designer vagina’
- <100 items found
- ‘laser labiaplasty’
- 33 items found

‘designer vagina’
>37,000 items found
‘laser labiaplasty’

378 items found

L’aumento della richiesta di trattamenti

- **70% aumento del numero di donne che richiedono labioplastica in NHS**
- **404 procedure nel 2006**
- **1118 procedure nel 2008**

Liao et al, 2009

- **Piu di 5000 donne hanno richiesto chirurgia cosmetica dei genitli nel 2010**
- **65% riduzione piccole labbra**
- **35% restringimento e rimodellamento**

Harley Medical Group

Indicazione alla chirurgia estetica genitale

- **Miglioramento estetico**
- **Aumento del piacere sessuale**
- **Miglioramento della funzione**

Cosmetic Genital Surgery

- **53 women complaining of vaginal laxity**
- **All underwent colpoperineoplasty**
- **At 6 months;**
- **94% experienced a tighter vagina and said they were able to achieve orgasm**
- **74% of patients felt surgery fulfilled their expectations**
- **5% felt that surgery did not meet their expectations**
- **4% regretted surgery**

Pardo et al, 2006

Funzioni della Vulva

Apertura del canale vaginale	*introito vaginale*
"doppia porta"	*Le labbra maggiori e minori proteggono l'apertura del canale vaginale*
Benessere vulvovaginale	*Assicura un benessera vaginale e necessita di semplici lavaggi*
Funzione sessuale	*E' ricca di fibbre sensitive Induce piacere quando è stimolata*
Uretra	*Contiene il meato uretrale*

Aging…

The Three Ages of Woman
Gustav Klimt - 1905

Perineal Lacerations

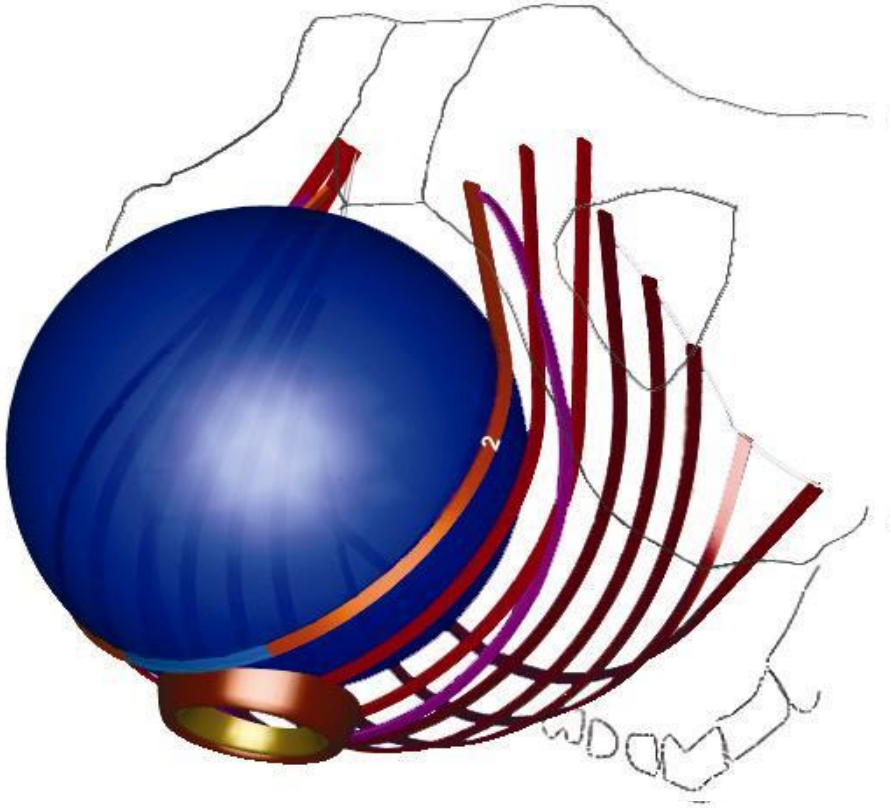

Lien KC. Obstet Gynecol 2004; 103: 31-40

Vulvar pathology…



Malformations…

Mutilations…

Estrema variabilità del range di **NORMALITA'**

- Caratteristiche somatiche etniche
- Caratteristiche somatiche costituzionali (peso,altezza,ecc.)
- Variazioni somatiche nelle diverse fasi della vita
  - ✓ Gravidanza e parto
  - ✓ Stato ormonale / Menopausa
  - ✓ Attività sessuale
- Caratteristiche degli organi pari e simmetrici, mai identici

Estrema variabilità del range di **NORMALITA'**

- Monte di Venere
- Grandi labbra
- Clitoride
- Piccole labbra
  - ✓ Morfologia
  - ✓ Ampiezza / Lunghezza
  - ✓ Origine / Inserzione
- Forchetta
- Vestibolo vaginale

VULVA
visione antero-posteriore

anteriore/ventrale

Monte di Venere

Grandi Labbra

Lunghezza = 7-8 cm

Larghezza = 2-3 cm

spessore = 15-20 mm

Solco Genito-Femorale

Piccole Labbra

Lunghezza = 30-35 mm

Larghezza = 10-15 mm

spessore = 4-5 mm

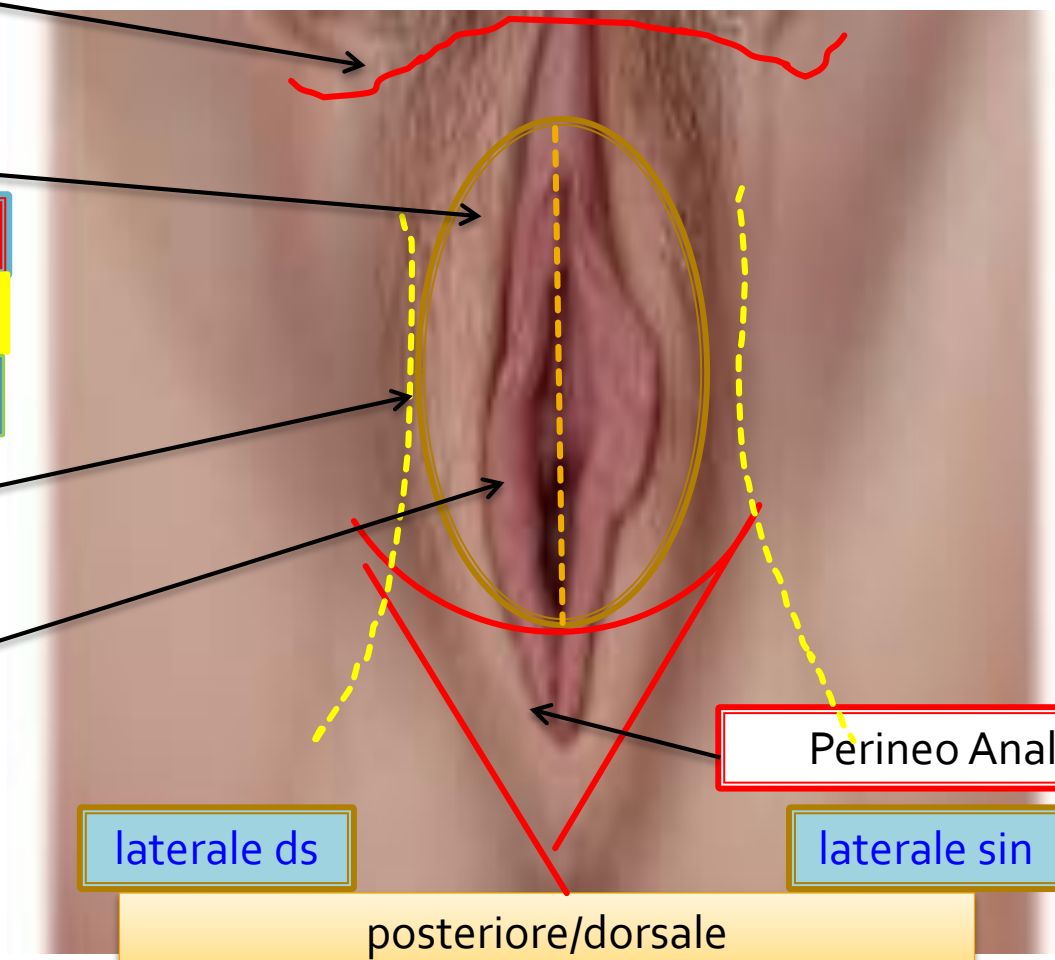

Perineo Anale

laterale ds

laterale sin

posteriore/dorsale

ANATOMIA FUNZIONALE GRANDE LABBRO

- ✓ Protezione meccanica di tutta l'area vulvare
- ✓ Protezione delle piccole labbra
- ✓ Concorre alla chiusura vaginale
- ✓ Presenza di ghiandole sebacee di protezione fisico-chimica contro la macerazione tissutale
- ✓ Le secrezioni rappresentano un elemento di attrazione sessuale

Anatomia → **Funzione**

ANATOMIA FUNZIONALE PICCOLO LABBRO

Osservazioni cliniche:

- ✓ protezione meccanica introito vaginale (e uretra)
- ✓ protezione fisico-chimica: barriera ghiandole sebacee

Anatomia → **Funzione**

Modificazioni anatomiche

- ✓ Ipoplasia vulvare
- ✓ Inserzione nella commissura posteriore

Vulvo-vaginiti micotico-batteriche, Cistiti ricorrenti,
Discomfort attività quotidiane
DISCOMFORT FUNZIONALE / ESTETICO

Punti riferimenti e dimensioni del clitoride

Lunghezza corona del glande 6-7mm

Larghezza 7 mm

Lunghezza totale 20-30 mm

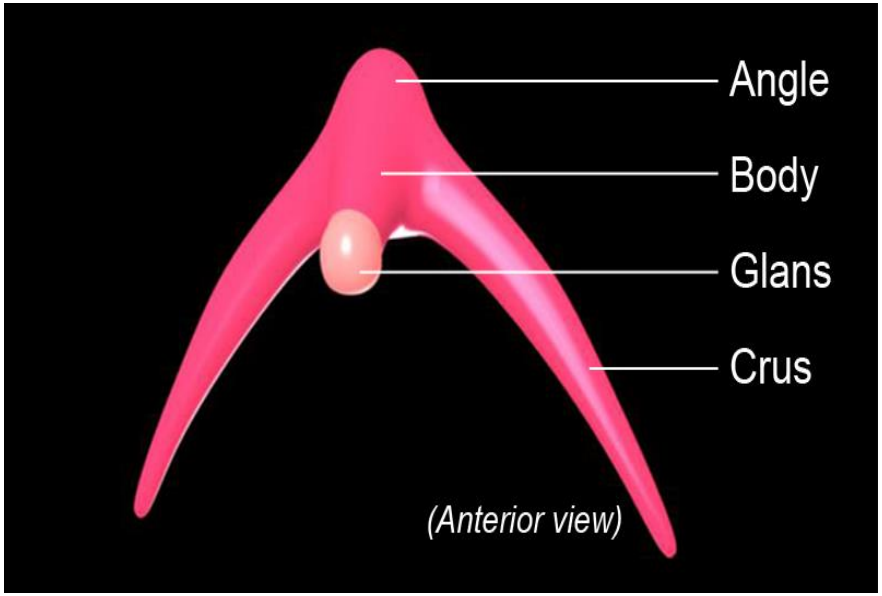

Verkauf BS. Obstet Gynecol 1992;80:41 -44

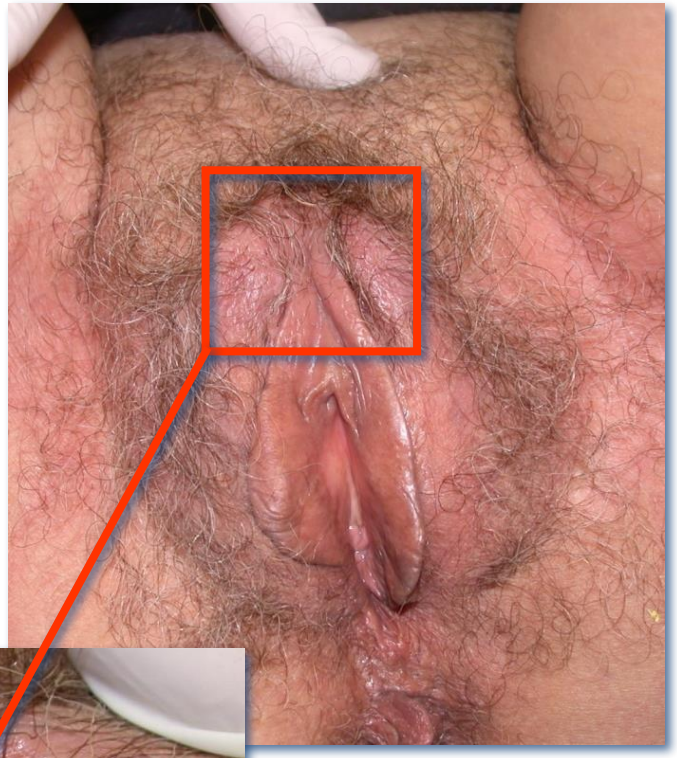

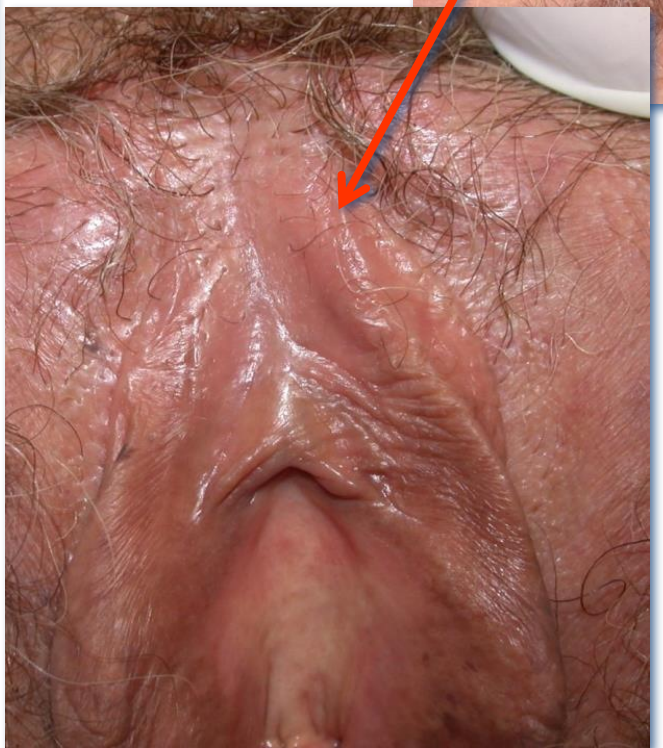

Variabilità anatomiche

- ✓ Rapporto piccole labbra /
- ✓ volume e lunghezza grandi labbra e Monte di Venere

- ✓ Rapporto forchetta / distanza ano-clitoride

Piccolo labbro, inserzione (estremi opposti):

- ✓ **Ipoplasia vulvare**
- ✓ **Inserzione nella commissura posteriore**

↓

Vulvo-vaginiti micotico-batteriche, Cistiti ricorrenti, Discomfort estetico e delle attività quotidiane

IPOPLASIA PICCOLO LABBRO

VARIABILITA' ANATOMICA

Morfologia

DISCOMFORT FUNZIONALE / ESTETICO

INSERZIONE ALLA COMMISSURA POSTERIORE

FORCHETTA VAGINALE a "U"

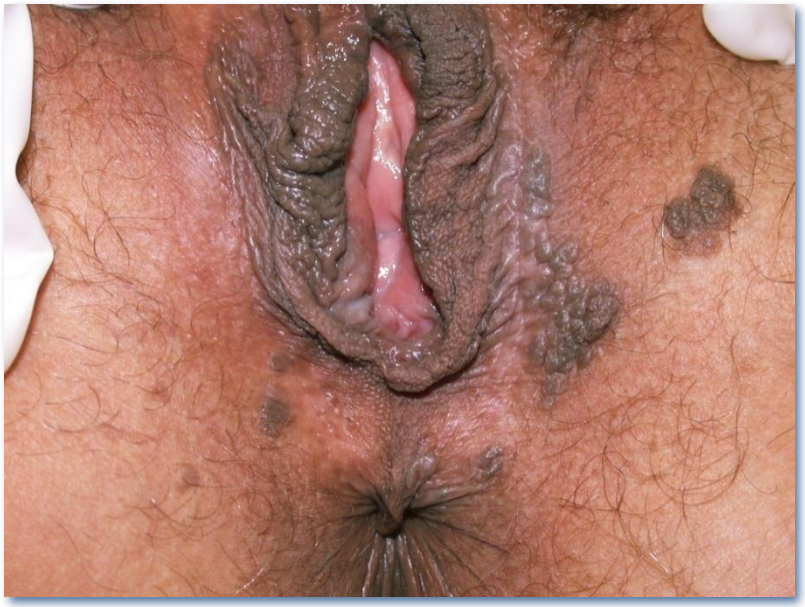

DISCOMFORT FUNZIONALE / ESTETICO

IPERTROFIA PICCOLO LABBRO

VARIABILITA' ANATOMICA

AMPIEZZA

DISCOMFORT FUNZIONALE / ESTETICO

Labioplastica e Plastica Vestibolare

Vestibular plasty

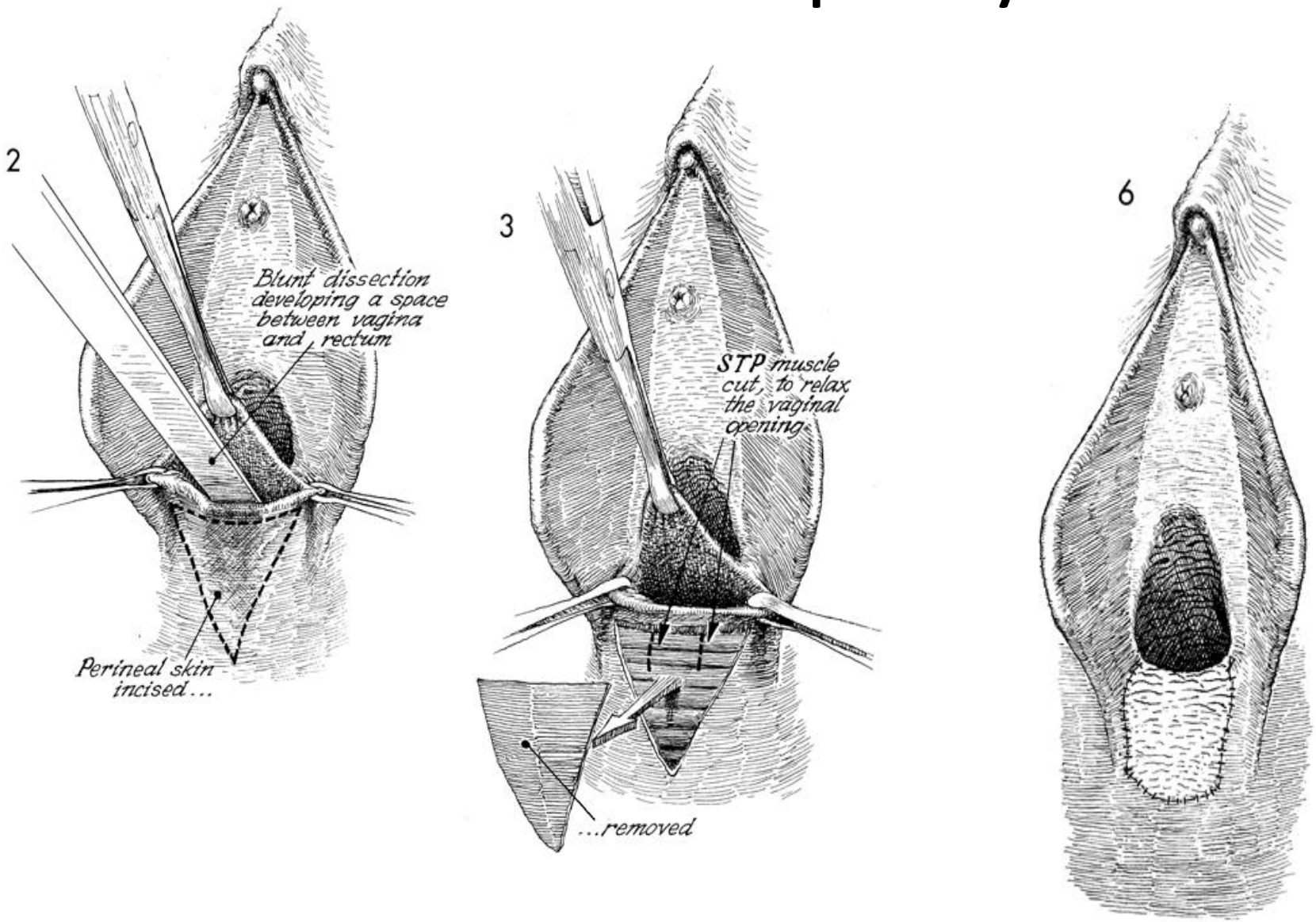

Vestibular Z-plasty

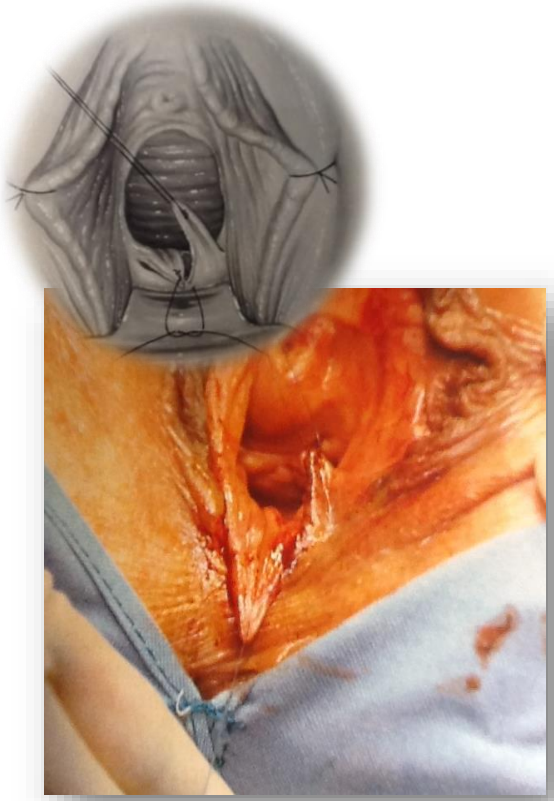

Labia Minora Hypertrophy (cysts retention)

Hypertrophic Angiokeratomas of Labia Majora

10

16 yrs

Complications

Documeted

- Wound dehiscence (5.4% -7%)
- Postoperative discomfort (23%)
- Superficial dyspareunia (median 28 days)
- Hematoma formation

Potential

- Infection
- Altered sensation
- Dyspareunia
- Adhesions

Di Saia JP. J Sex Med 2008;5:1263-1267

ACOG Committee Opinion #378, 2007

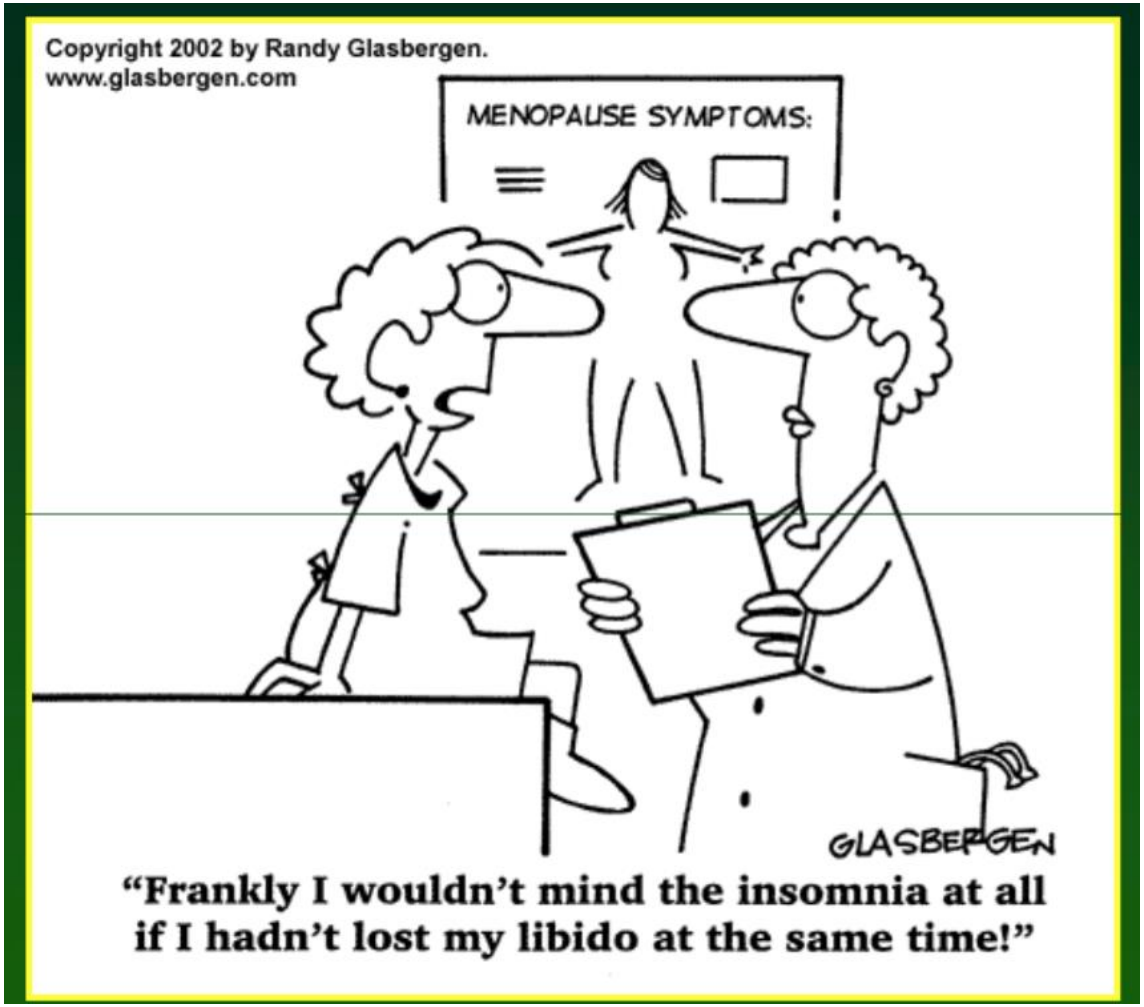

"Frankly I wouldn't mind the insomnia at all if I hadn't lost my libido at the same time!"

CLIMACTERIC 2014;17:1–7

A 12-week treatment with fractional CO_2 laser for vulvovaginal atrophy: a pilot study

S. Salvatore, R. E. Nappi, N. Zerbinati†, A. Calligaro‡, S. Ferrero**, M. Origoni, M. Candiani and U. Leone Roberti Maggiore*

Department of Obstetrics and Gynecology, Vita-Salute San Raffaele University and IRCCS San Raffaele Hospital, Milan; *IRCCS Policlinico S. Matteo Foundation and Department of Clinical, Surgical, Diagnostic and Pediatric Sciences, University of Pavia, Pavia; †University of Insubria, Varese; ‡University of Pavia, Pavia; **Department of Obstetrics and Gynecology, San Martino Hospital and National Institute for Cancer Research, University of Genoa, Genoa, Italy

Key words: FRACTIONAL CO_2 LASER, MENOPAUSE, VAGINAL DRYNESS, DYSPAREUNIA, VULVOVAGINAL ATROPHY

ABSTRACT

Objective This pilot study aimed to assess the efficacy and feasibility of fractional CO_2 laser in the treatment of vulvovaginal atrophy (VVA) in postmenopausal women.

Methods VVA symptoms were assessed before and after three applications of laser over 12 weeks in 50 women (age 59.6 ± 5.8 years) dissatisfied with previous local estrogen therapies. Subjective (visual analog scale) and objective (Vaginal Health Index Score, VHIS) measures were used during the study period to assess VVA. Quality of life was measured by using the SF-12. A subjective scale to evaluate the degree of pain related to the laser application and the degree of difficulty to perform the laser procedure was used.

Results Fractional CO_2 laser treatment was effective to improve VVA symptoms (vaginal dryness, vaginal burning, vaginal itching, dyspareunia, dysuria; $p < 0.001$) at 12-week follow-up, as well as the VHIS (13.1 ± 2.5 at baseline vs. 23.1 ± 1.9; $p < 0.001$). Both physical and mental scores of quality of life were significantly improved in comparison with baseline ($p < 0.001$). Satisfaction with the laser procedure was reported by 42 women (84%) and a minimal discomfort was experienced at the first laser application, mainly because of the insertion and the movements of the probe. Finally, the technique was very easy to perform in all women starting from the second application at week 4 and no adverse events were recorded during the study period.

Conclusions A 12-week treatment with the fractional CO_2 laser was feasible and induced a significant improvement of VVA symptoms by ameliorating vaginal health in postmenopausal women. Further controlled studies should be performed to confirm the present data and to assess the long-term effects of the laser procedure on vaginal tissues.

Archives of Gynecology and Obstetrics
November 2017, Volume 296, Issue 5, pp 973–978 | Cite as

Long-term reliability of fractioned CO_2 laser as a treatment for vulvovaginal atrophy (VVA) symptoms

Authors Authors and affiliations

Annalisa Pieralli, Claudia Bianchi, Manuela Longinotti, Serena Corioni, Noemi Auzzi, Angelamaria Becorpi, Maria Grazia Fallani, Giuseppe Cariti, Felice Petraglia

Long-term data showed that the improvement of vaginal health may continue up to 24 months after fractional CO_2 laser treatment although between 18 and 24 months benefits decline, and approximately 80% of women decide to start a new treatment cycle of laser applications.

Table 1 Patients' demographic characteristics

Spontaneous menopause	128
Oncological menopause	56
Mean age	
Spontaneous menopause	57, 76
Oncological menopause	53, 76
Time from onset of menopause	
Spontaneous menopause	8, 8
Oncological menopause	6, 3
Nulliparous	117
Previous hysterectomy	36

Arch Gynecol Obstet, 2017

Fig. 2 Patients' satisfaction rate during the follow-up period. We observed a decline in patient's satisfaction between 18 and 24 months after laser therapy

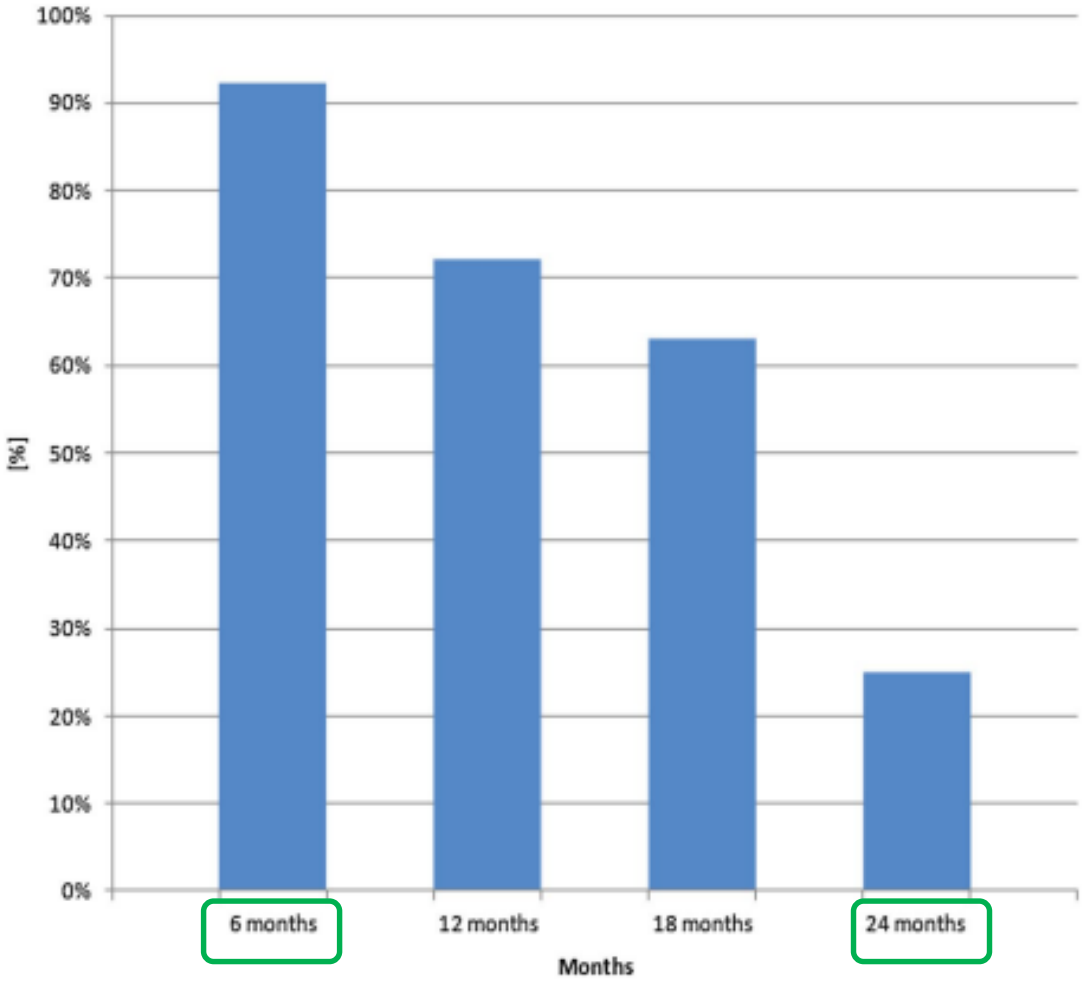

Arch Gynecol Obstet, 2017

Fig. 3 Patients' satisfaction rate during follow-up period in two groups: spontaneous and oncological menopause

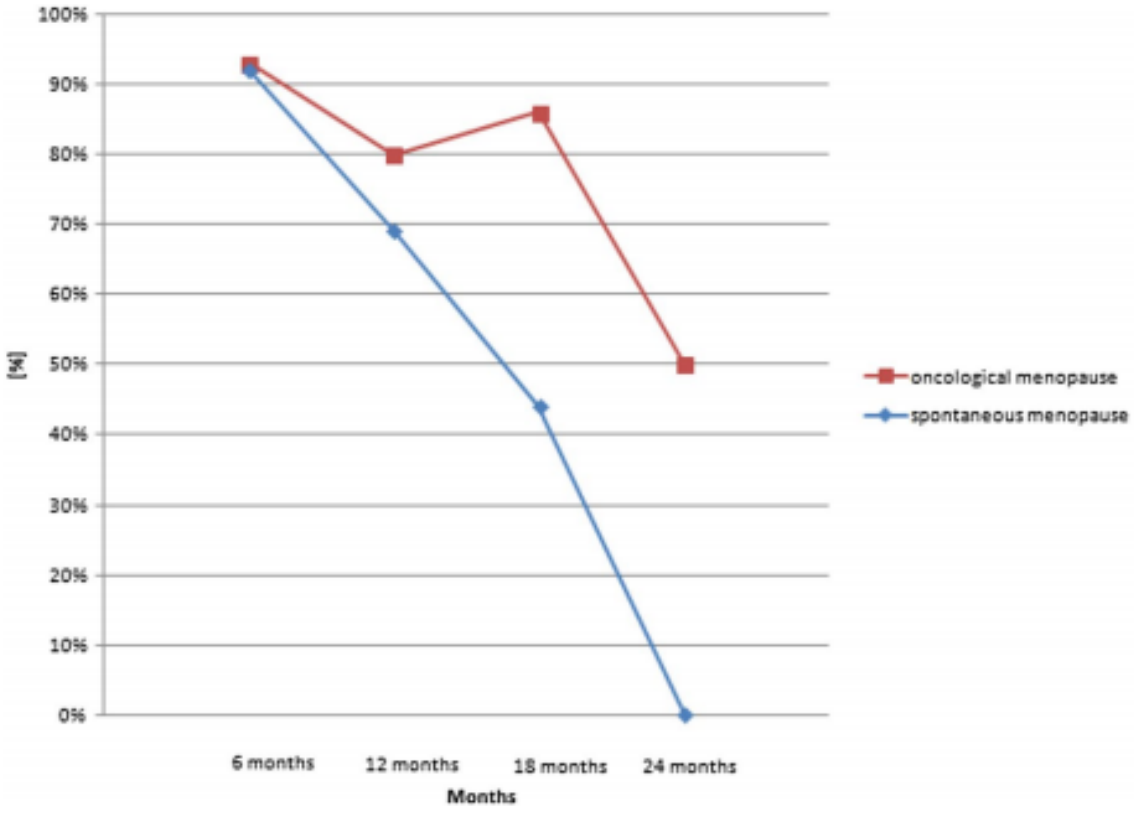

Arch Gynecol Obstet, 2017

SMOOTH™ mode pulse

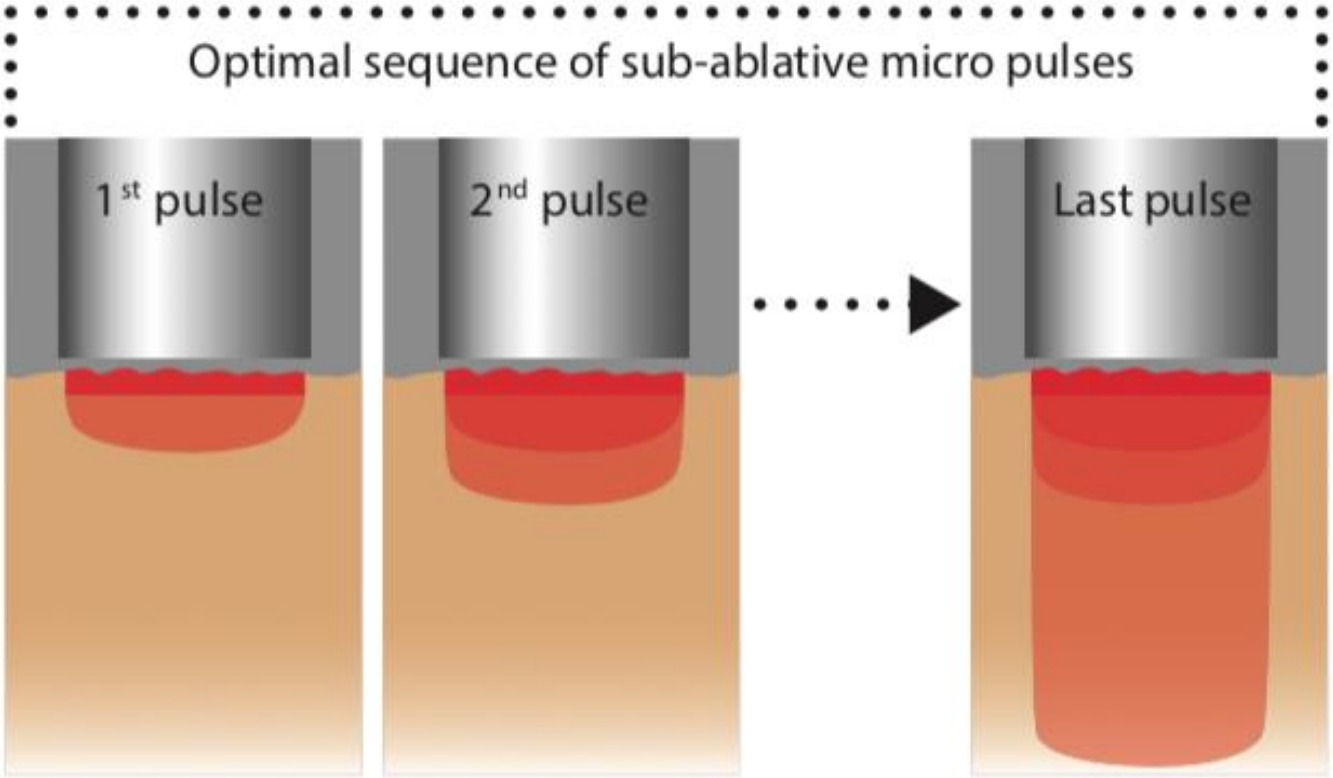

Unique sequential SMOOTH mode Er:YAG laser pulses generate an optimal structure of heat waves.

MECHANISM OF ACTION

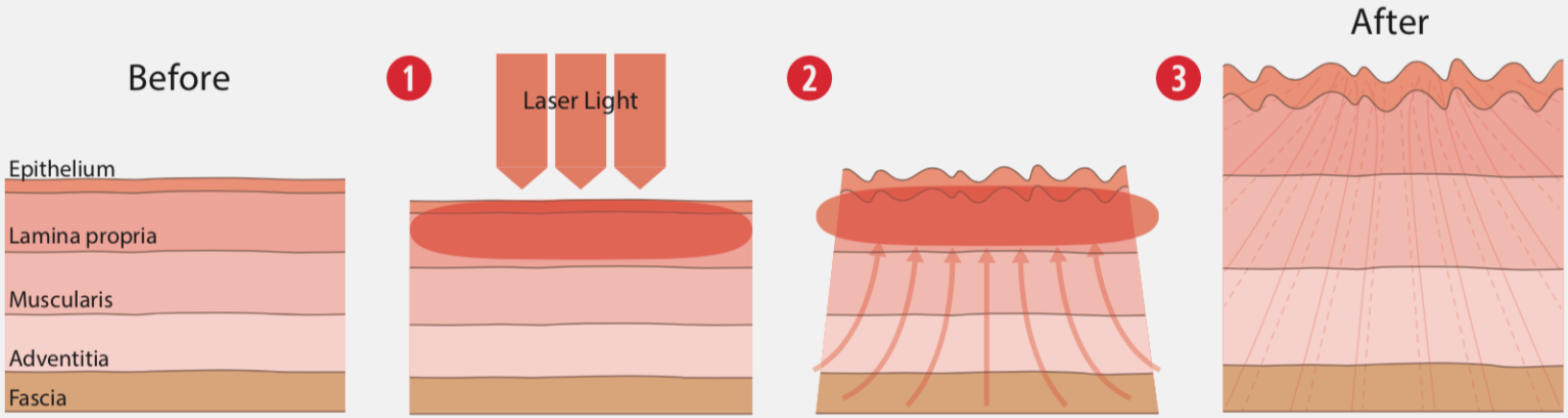

Vaginal wall structure

Photo-thermal heatwaves reaching up to 0.5 mm bellow the vaginal mucosa surface. Collagen fibers get shorter and thicker as a result of heat-induced collagen remodelling.

Deeper tissue layers get pulled up and tightened by the remodelled superficial tissue layer.

Vaginal walls are further strengthened by the process of neo-collagen-esis (formation of new collagen fibers).

Mayer-von-Rokitansky-Kuster-Hauser Syndrome

Laparoscopic exploration

Perineal approach:
skin incision,
neo-canal creation in
the urethral rectum space

Perineal approach: neovaginal canal creation, peritoneum opening

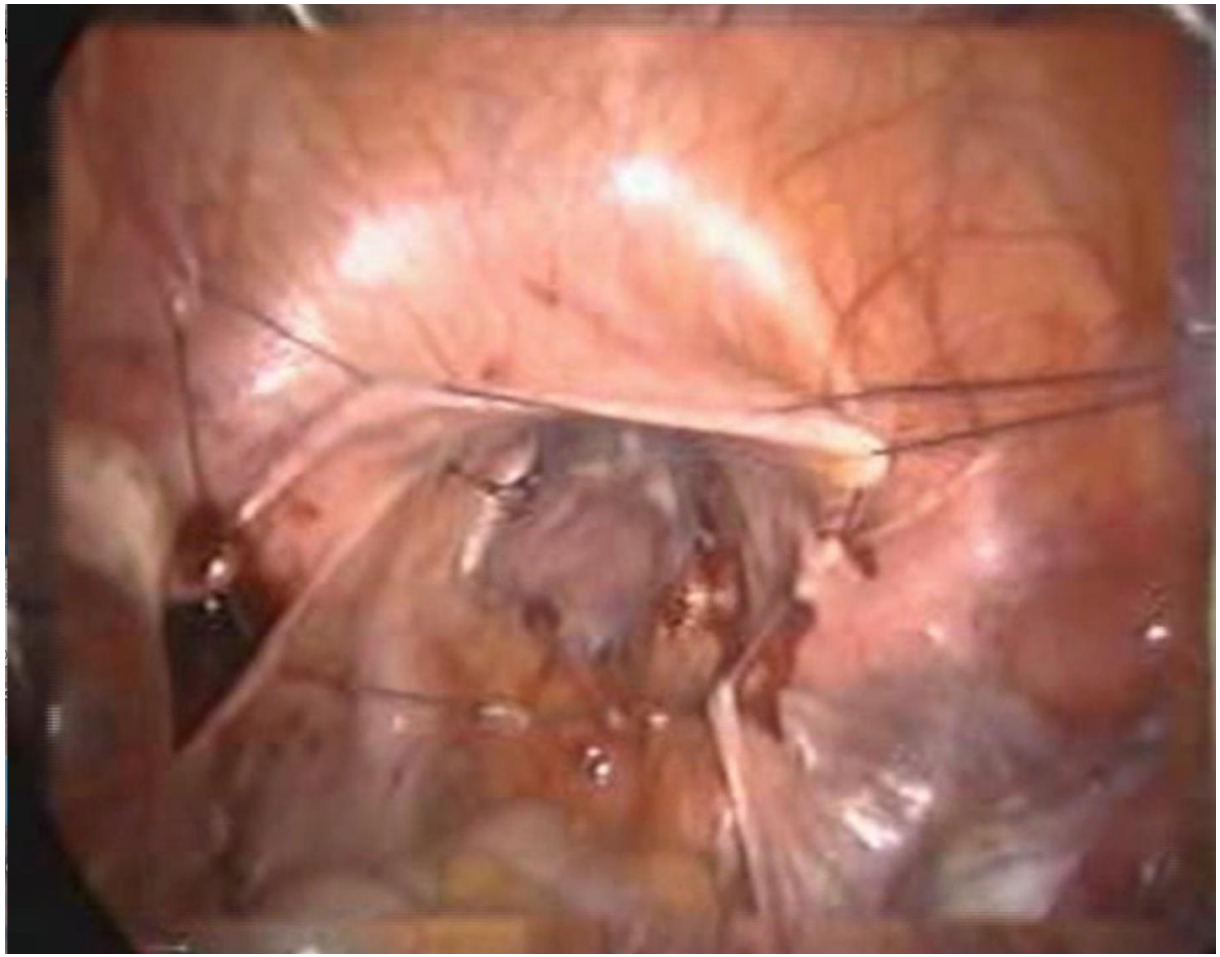

RESULTS

4 months later

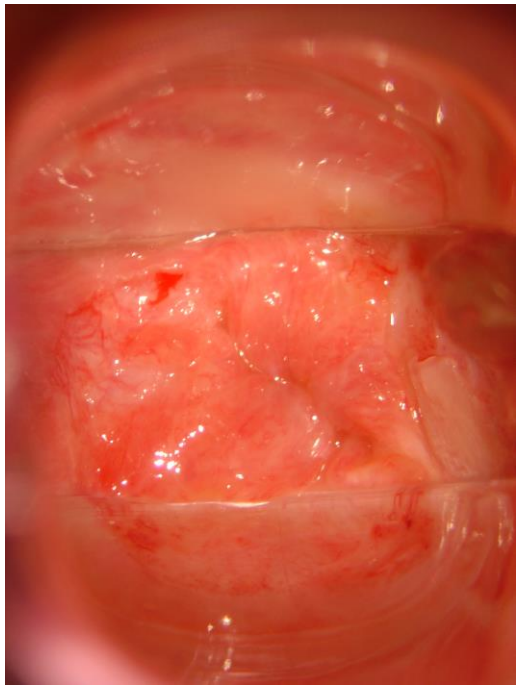

LAPAROSCOPIC PERITONEAL COLPOPOIESIS

RESULTS

NEOVAGINOPLASTY FOLLOW-UP: LM and TEM evaluation

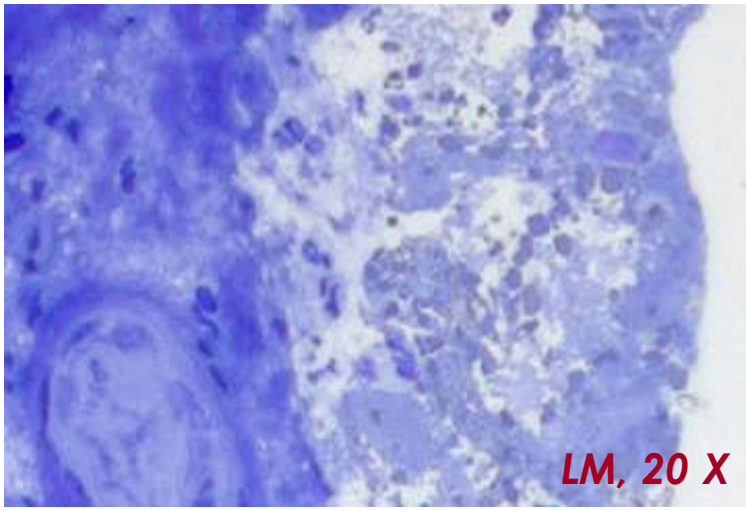

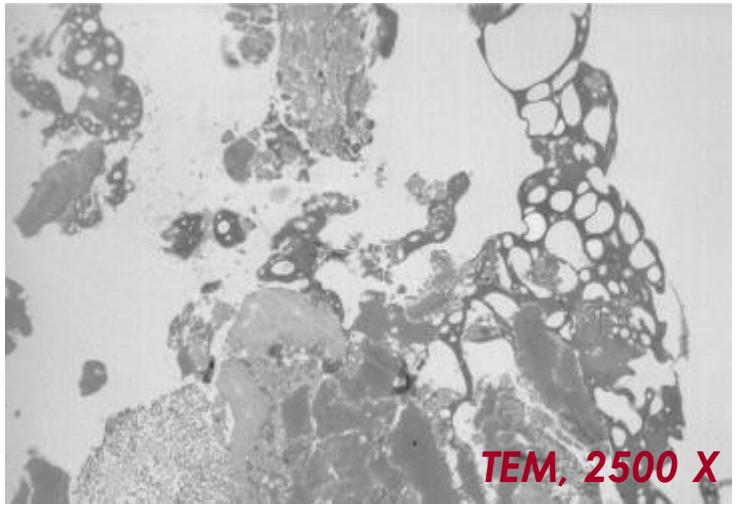

Surgery:
March, 2005

Biopsy:
June, 2005

Irregularly-shaped neovaginal wall

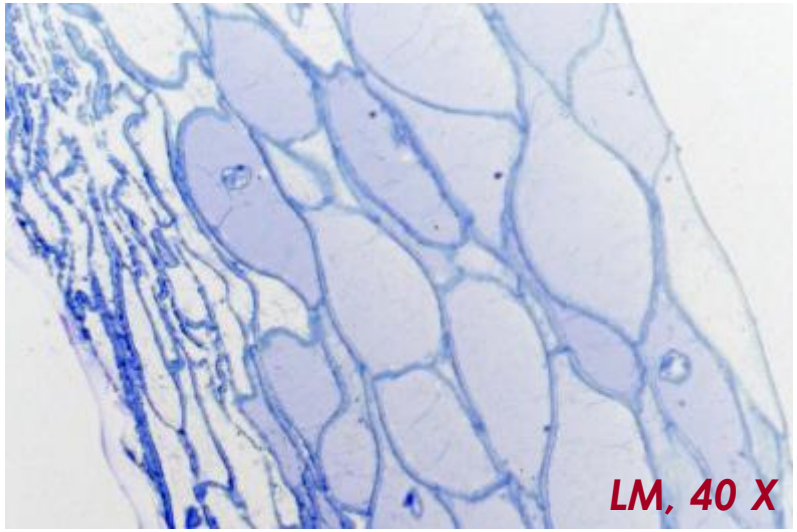



Surgery:
March, 2005

Biopsy:
Dec , 2005

Presence of squamous stratified epithelium lining the neovaginal wall

Dati Clinici

Sede prelievo : Neo-vagina

Dati clinici : Dato non disponibile

Mat. in esame : Scraping

Camp.in esame: Campione strisciato su vetrino

Dr. Saccucci

Sig : ME

Via :

Cap : Citta' :

Data di nascita: 00/00/00 Tel:

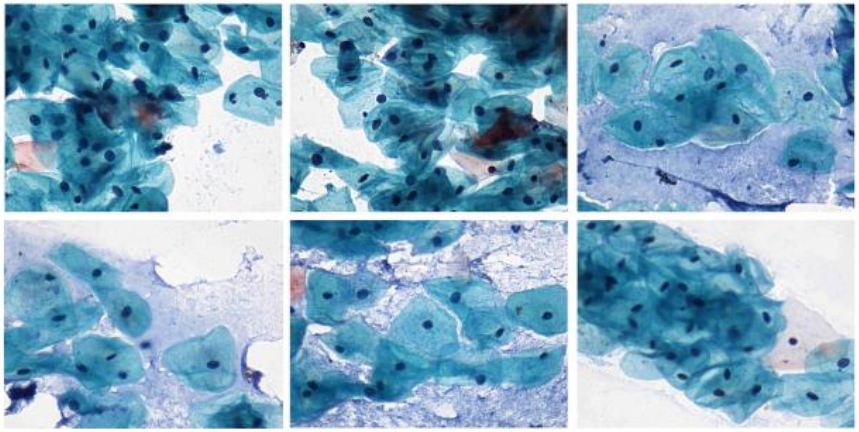

Valutazione Microscopica

Soddisfacente per la valutazione.Modico essudato leucocitario. Cellule di sfaldamento in prevalenza superficiali ed intermedie. Flora batterica costituita da B. Di Doderlein.

Valutazione diagnostica

Assenza di lesioni intraepiteliali o neoplastiche maligne nello striscio esaminato.

Data : 14/09/2012

Dr. Antonio Pasciuto
Specialista in Anatomia Patologica

PRINCIPALI AREE DI INTERESSE E SVILIUPPO

- Labioplastica maggiore e minore
- Plastica prepuzio clitorideo, vestibolo
- Lipofiller grandi labbra
- Trattamento atrofia/distrofia vaginale (ac.ialuronico, PRP, laser, elettroporzione carbossiterapia)
- Laser lipo-lisi sovrapubica
- Trattamento della vulvodinia
- Trattamento delle mutilazioni genitali femminili e delle malformazioni congenite vulvo-vaginali
- Trattamento incontinenza urinaria con laser, con tossina botulinica tipo A
- Patologia dermatologica e detersione vulvare
- Tightening e reshaping

4° CONGRESSO NAZIONALE AIGEF

FACTOR V

MILANO - 4/5 APRILE 2019

AIGEF

Associazione Italiana Ginecologia Estetica e Funzionale

Segreteria Scientifica
Via Domenico Chiellini, 16 - 00197 Roma - info@aigef.com

www.aigef.com